

Experimentally induced depletion of germ cells in sub-adult Patagonian pejerrey (*Odontesthes hatcheri*)

S.K. Majhi^a, R.S. Hattori^a, Sk.M. Rahman^b, T. Suzuki^b, C.A. Strüssmann^{a,*}

^a Department of Marine Bioscience, Tokyo University of Marine Science and Technology, Konan 4-5-7, Minato-Ku, Tokyo 108-8477, Japan

^b Department of Food Science, Tokyo University of Marine Science and Technology, Konan 4-5-7, Minato-Ku, Tokyo 108-8477, Japan

Received 17 September 2008; received in revised form 26 November 2008; accepted 8 December 2008

Abstract

Germ cell (GC) transplantation (GCT) is a novel reproductive technology with application in seed production and conservation of endangered species. This study examined the suitability of treatment with Busulfan, a cytotoxic agent, and warm water, known to cause GC degeneration, for depletion of endogenous GCs in sub-adult Patagonian pejerrey *Odontesthes hatcheri* intended as hosts in GCT. In two experiments, fish were treated with six combinations of temperature (intermediate and high, 20 and 25 °C, respectively) and Busulfan (0, 20, and 40 mg/kg body weight), given intraperitoneally (ip) as a single (0 week) or repeated (0 and 4 week) dose. The effectiveness of the treatments was assessed by gonado-somatic index, histology, and (germ cell-specific) *vasa* gene expression after 8 weeks. Fish were allowed to recover at 17 °C for 4–8 weeks after the treatments to ascertain the permanency of the effects. The high temperature (25 °C) alone induced only incipient gonadal degeneration and germ cell loss, but was highly effective in combination with double administration of 40 mg/kg Busulfan. Males tolerated Busulfan better and were more easily depleted of germ cells than females. Animals treated for 8 weeks were severely devoid of germ cells, but were still capable of gametogenesis. Thus, the combination of Busulfan and high water temperature appeared to be efficient for depletion of GCs in adult fish; and the treated gonads retained the ability to support GC proliferation and differentiation. Furthermore, quantitative analysis of *vasa* transcript levels was found to be an useful to monitor the degree of gonad sterility during treatment. © 2009 Published by Elsevier Inc.

Keywords: Busulfan; Germ cell transplantation; Sterilization; *Odontesthes hatcheri*; Heat

1. Introduction

Germ cell transplantation (GCT), first demonstrated in the mouse [1], is a promising reproductive technology with potential application in animal production and conservation of endangered species, ranging from fish to mammals. This procedure, based on the implantation of donor germ cells (GCs) into the

gonads of a surrogate (recipient) animal, allows the rapid and theoretically unlimited production of gametes from the donor without interference from the host's genome, i.e. animals produced with transplanted gametes are not transgenic. Thus, highly productive individuals could be propagated far in excess of their reproductive capacity and beyond their lifespan without resorting to time-consuming procedures of gamete collection, cryopreservation, and AI. In addition, GCs could be harvested from immature as well as aging donor animals and be induced to develop into functional gametes by insertion into an adult, sexually competent animal. Consequently, this procedure offers a way to

* Corresponding author. Tel.: +81 3 5463 0541; fax: +81 3 5463 0541.

E-mail address: carlos@kaiyodai.ac.jp (C.A. Strüssmann).

preserve genes from animals that might otherwise die prior to sexual maturity or become senile; this is extremely important in the case of rare, endangered species. There has been recently a great interest in the application of GCT to aquatic animals, in particular fish [2,3]. Fishes are generally prolific and GCT using related species as recipients could be used to propagate commercially important species which are too large for hatchery rearing, that do not spawn due to the stress of confinement, or whose maturation cycle is associated with complex migratory behavior which cannot be reproduced in captivity.

One of the preconditions for GCT is the availability of a suitable host species whose gonads can support the development of the donor's germ cells and which meets the requirements of easy maintenance and breeding in captivity. Closely related species generally meet the physiological and immunological requirements for donor cell development, but the recipient animal must first be artificially depleted of its GCs to obtain a higher relative yield of donor-derived gametes [4]. For instance, Brinster et al. reported that the introduced cells have improved access to the basal compartment of seminiferous tubules when the recipient testis was depleted of endogenous GCs prior to transplantation [4]. Several options for eradication of GCs have been tested in mammals, including treatment with cytotoxic drugs like Busulfan [5], irradiation [6], cold ischemia [7], and hyperthermia [8]. Some of these methods have also been tried on fish [3,9–15], but conditions for rapid and efficient depletion of GCs with general applicability have not been established. An alternative method is to perform transplantation into triploid gonads [16] as triploid fish are generally, though not always, sterile [17–19]. Although this is an ingenious strategy, it requires long-term rearing of recipient animals to adulthood, as triploids can be produced only by chromosome manipulation performed shortly after fertilization or by crossing between diploid and tetraploid fish [17]. On the contrary, the development of chemical and/or thermal protocols for sterilization of fish gonads might allow application in cases that require immediate attention, e.g. species facing imminent extinction and for which suitable triploid hosts are not available.

In this context, the objective of the present study was to examine the suitability of treatments with Busulfan and warm water to induce depletion of endogenous GCs in sub-adult fish using the Patagonian pejerrey, *Odontesthes hatcheri*, as a model. The Patagonian pejerrey is a freshwater species that inhabits relatively cool waters (5–25 °C) and that spawns easily in captivity [20]. Males and females attain sexual

maturation between 1 and 2 years of age and remain reproductively competent for at least 5 years (C.A. Strüssmann, unpublished observations). This species was chosen as a model in this study because of the information available on the effects of high temperatures (e.g. ≥ 25 °C) on its gonadal function [10,20] and because it would be a suitable host for future experiments on GCT, using the congeneric species *Odontesthes bonariensis* as the GC donor. Two experiments were conducted in this study, the first only with males and the second with both males and females, wherein the effectiveness of the treatments was evaluated by gonado-somatic index (GSI) determination, qualitative and quantitative (changes in GC number) histological observations, and the ability of treated gonads to support gametogenesis. In addition, we also examined the suitability of the GC-specific *vasa* gene transcript level as a molecular tool to monitor the degree of GC depletion in treated fish.

2. Materials and methods

2.1. Experimental materials and rearing protocol

One-year-old (sub-adult) Patagonian pejerrey used in the experiments were produced at the rearing facilities of the Tokyo University of Marine Science and Technology at Shinagawa Campus (first experiment; only males; mean \pm S.D. body weight of 28.2 ± 10.8 g; $n = 26$ for each treatment) and Field Science Center, Yoshida Station (second experiment; both sexes; body weight 23.3 ± 9.3 g for males and 20.5 ± 11.5 g for females; $n = 50$ for each sex). Fish were stocked in 200 L tanks at a density of 6.3 kg of fish/m³ and reared in flowing brackish water (0.2–0.5% NaCl) under a constant light cycle (15L9D). Animals were fed with pelleted commercial diet four times per day to satiation. Prior to treatments, all groups were acclimated for 2 weeks at 17 °C.

2.2. Experimental treatments

The first experiment, using only males, tested four combinations of Busulfan (20 and 40 mg/kg body weight) and temperature (20 and 25 °C), whereas a fifth group received only the vehicle (DMSO) at 20 °C and served as a control (hence, groups were designated B20T20, B20T25, B40T20, B40T25, and B0T20). Each group was divided in two subgroups at 4 weeks, with half of the fish receiving a booster treatment of the same dosage as the previous one. All subgroups were then reared separately until termination of the experiment at

8 weeks. In the second experiment, animals of both sexes were reared at 25 °C and received either treatments of 40 mg/kg Busulfan (B40T25) or only the vehicle (B0T25), both with a booster dosage at 4 weeks. This experiment was conducted to confirm the results of the first one, which showed marked GC depletion at the highest Busulfan dosage and temperature, to discriminate between the effects of high temperature (25 °C) and the drug, and to ascertain the effects in females. Moreover, fish in the second experiment were reared at 17 °C for an additional 8 weeks after termination (recovery period) for observation of the permanency of the treatment effects. As described in Section 3, some treatments caused almost, but not complete sterilization. Therefore, improvement in gonadal conditions with proliferation of GCs and gamete formation was taken as an indication of the capacity of the gonads to support gametogenesis.

Busulfan dosages were based on published information on effective dosages for mice [5,21]. The choice of temperatures was based on our previous reports regarding germ cell-deficient fish among *O. hatcheri* exposed to warm water during the juvenile stage [10,20]. Busulfan (Sigma–Aldrich, St. Louis, MO, USA) was first dissolved in dimethyl sulfoxide (DMSO, Wako Pure Chemicals Ind., Osaka, Japan) and then further diluted with freshwater fish Ringer solution to reach working concentrations. The limit of solubility for Busulfan in aqueous media is ~4 mg/mL. Thus, to avoid precipitation, it was mixed with fish Ringer solution just before use and maintained at room temperature. For treatment, the fish were anesthetized using 2-phenoxyethanol (Wako Pure Chemicals Ind.) and body weight and length were recorded. Busulfan was administered ip with a 500- μ L microsyringe (Hamilton, NV, USA).

2.3. Sampling schedule and histological analysis of the gonads

For histological observation, fish ($n = 2\text{--}5$ per sex) were randomly sampled from each group at 2, 4 and 8

weeks after the beginning of the treatments. Animals from the second experiment that were reared at 17 °C after 8 weeks were also sampled at 12 and 16 weeks. Fish were killed by anesthetic overdose and body weight recorded. The gonads were excised, macroscopically examined, photographed using a digital camera, and weighed to the nearest 0.01 g. The middle portion of the right and left gonads from each fish were then immersed in Bouin's fixative for 24 h and preserved in 70% ethanol. Gonads were processed for examination with light microscopy, using routine histological procedures including sectioning at 5 μ m and staining with hematoxylin–eosin. Approximately 100–150 serial histological sections from each fish were examined under a microscope at magnifications from 10 to 100 \times . The degree of histological degeneration and germ cell loss of each specimen was classified following criteria published previously [11–14], with minor modifications (Table 1). Digital images taken from five representative histological sections of the right and left lobes of the gonad of each individual in the 2nd experiment were used for determination of the number of spermatogonia or oogonia per section and the cross-section area of the gonad using the Image-Pro Plus Software, Version 4.0 (Media Cybernetics, Silver Spring, MD, USA).

2.4. Vasa expression analysis

The usefulness of *vasa* expression analysis as a tool to monitor the degree of germ cell loss in experimentally neutered *O. hatcheri* was examined by in situ hybridization (ISH) and Real-Time RT-PCR analysis, using males from the first experiment. For *vasa* ISH, a piece of testis from the control group was fixed in 4% paraformaldehyde in PBS (pH 7.4) overnight at 4 °C, dehydrated in ethanol series, and embedded in paraffin. Transversal sections were cut in a microtome (thickness, 6 μ m) and mounted on to glass slides. Sections were pre-treated in 1 μ g/mL proteinase K for 10 min (25 °C) and then hybridized with 150 μ L of digoxigenin

Table 1
Histological criteria for classification of gonadal integrity/degeneration in sub-adult Patagonian pejerrey.

Males	Histological category	Females
Conspicuous cysts of spermatogonia and other spermatogenic stages	I	Presence of cysts of oogonia interspersed with oocytes at various stages of development
Only cysts of spermatogonia; efferent ducts may or not contain residual spermatozoa	II	Light hypertrophy of the ovigerous lamellae; oocytes fewer and atretic
Cysts of spermatogonia are few and small	III	Few if any oocytes and greatly reduced number of oogonia
Absence of spermatogonia	IV	Absence of oogonia

(Roche Diagnostic)-labeled sense and antisense probes at 50 °C overnight. *Vasa* probes were synthesized using primers constructed based on a sequence for *O. hatcheri* available in the GenBank (accession number #DQ441593). T7 and T3 phage promoter sequences were appended to the forward (5-GTA ATA CGA CTC ACT ATA GGG CCT CCA ACC AGG GAG CTC ATC AAC C-3) and reverse primers (5-GCA ATT AAC CCT CAC TAA AGG GGT GGC GCT GAA CAT CAG GGT CTG-3), respectively, for direct in vitro transcription using T7 and T3 RNA polymerase enzymes (Roche Diagnostic, Manheim, Germany). The hybridization signal was detected using Anti-DIG-AP (Roche Diagnostic) and NBT/BCIP (Roche Diagnostic).

Samples for Real-Time RT-PCR of *vasa* expression were taken at 8 weeks from the anterior part of the testes of animals that received a booster dose on the 4th week, and stored in RNAlater (Sigma–Aldrich, St. Louis, MO, USA) at –80 °C until further processing. Samples from group B20T20 were accidentally lost and could not be analyzed. The RNA was extracted using Trizol (Invitrogen Life Technology, Carlsbad, CA, USA) according to the manufacturer's protocol. The cDNA was synthesized using oligodT primers and superscript reverse transcriptase (Invitrogen Life Technology). Primers for Real-Time RT-PCR (5-CCT GGA AGC CAG GAA GTT TTC-3 and 5-GGT GCT GAC CCC ACC ATA GA-3) were designed using Primer Express (Version 2.0; Applied Biosystems, Foster City, CA, USA). The Real-Time PCRs were run in an ABI PRISM 7300 (Applied Biosystems) using Power SYBR[®] Green PCR Master Mix in a total volume of 15 µL, which included 25 ng of first strand cDNA and 5 pmol of each primer (β -actin was analyzed as an endogenous control). Quantification was performed using the standard curve method with four points and the ABI Prism 7300 Sequence Detection Software (Version 1.2; Applied Biosystems).

2.5. Statistical analysis

Data were analyzed by one-way analysis of variance (ANOVA), followed by the Tukey's multiple comparison test using Graphpad Prism Version 4.00 (Graphpad Software, San Diego, CA, USA). Data are presented as mean \pm S.D. and differences between groups were considered significant at $P < 0.05$.

3. Results

3.1. Survival and growth

Busulfan and high temperature (25 °C) treatments were generally well tolerated by males, with a minimum final survival rate of 88% in the B40T25 group that received the booster dosage at 4 weeks in experiment 1. The same treatment caused mortality rates of 20% and 10% in the females at the 6th and 7th week, respectively, of experiment 2 (results not shown). In both experiments, no mortality occurred after the 7th week. Mortalities were attributed to the toxic effects of Busulfan, as fish developed skin ulcerations and died within 2–3 days after the booster treatment. There were no significant changes in gonad-free body weight in any treatment compared to the control (results not shown).

3.2. Effects of Busulfan and high temperature on the testes

The GSI of males from all groups, including the controls, decreased steadily in both experiments between 1 and 8 weeks (Figs. 1 and 2). However, these decreases were much more pronounced in groups treated with the highest Busulfan dosage (B40T25), especially the groups receiving a booster treatment at 4 weeks. The testes of these males were visibly shrunken and had a dark coloration (compared to the testes of

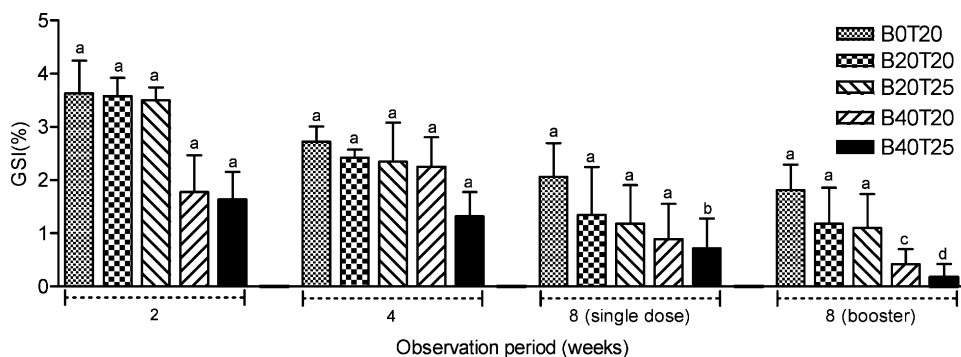


Fig. 1. Effects of Busulfan and high temperature on the gonado-somatic index of sub-adult Patagonian pejerrey males (experiment 1). a–d: Means without a common superscript differed ($P < 0.05$).

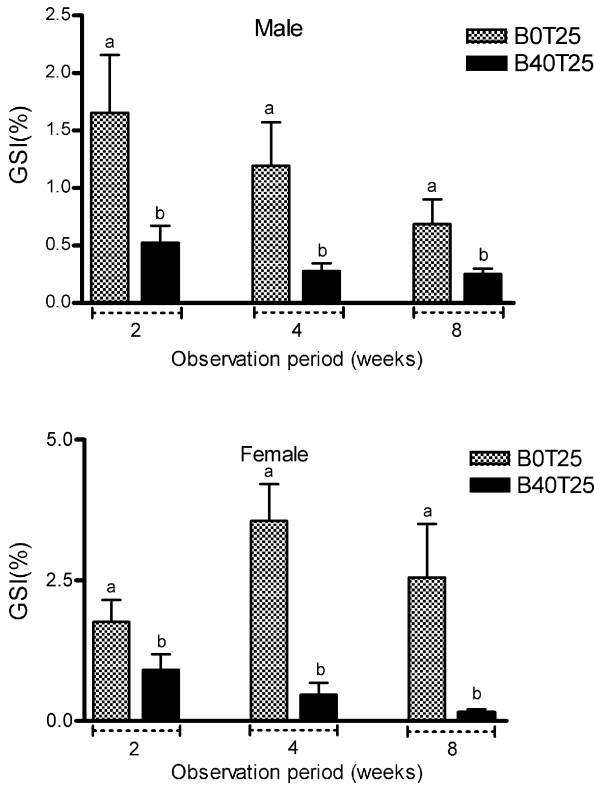


Fig. 2. Effects of Busulfan and high temperature on the gonadosomatic index of sub-adult Patagonian pejerrey males and females (experiment 2). a, b: Means without a common superscript differed ($P < 0.05$).

control animals) at 8 weeks (Fig. 3). Histologically, there was active spermatogenesis in all but one male not treated with Busulfan throughout the experiment (Tables 2 and 3; Fig. 4A–C). The exceptional individual from the control group, sampled after 8 weeks at 25 °C (2nd experiment), had only cysts of spermatogonia and lacked all other spermatogenic stages. Males treated

Table 2

Frequency of individuals per category of histological appearance of the testes in sub-adult Patagonian pejerrey (experiment 1).

Treatment	Observation period (week)	No. males			
		Histological category			
		I	II	III	IV
B0T20	2	4	–	–	–
	4	4	–	–	–
	8	2	–	–	–
	8 ^a	2	–	–	–
B20T20	2	–	4	–	–
	4	–	4	–	–
	8	–	2	–	–
	8 ^a	–	2	–	–
B20T25	2	–	4	–	–
	4	–	4	–	–
	8	–	2	–	–
	8 ^a	–	1	1	–
B40T20	2	–	4	–	–
	4	–	4	–	–
	8	–	2	–	–
	8 ^a	–	–	2	–
B40T25	2	–	4	–	–
	4	–	3	1	–
	8	–	2	–	–
	8 ^a	–	–	–	2

^a Given a booster dose at 4 weeks.

with a single dose of Busulfan lacked cysts of spermatocytes and spermatids, but still retained cysts of spermatogonia and some residual spermatozoa in the lumen of the seminiferous lobules and efferent ducts after 2–8 weeks, regardless of temperature (Fig. 4D). Some of these fish also had abnormal cells with variable size and staining properties, ranging from dense basophilic (hematoxylin-stained) to acidophilic (eosin-stained) bodies (Fig. 4D). Conversely, males




Fig. 3. Macroscopic appearance of the testes of Patagonian pejerrey in Busulfan-high temperature (B40T25; A) and control (B0T25; B) groups 8 weeks after the beginning of the treatment. Scale bars indicate 1 cm.

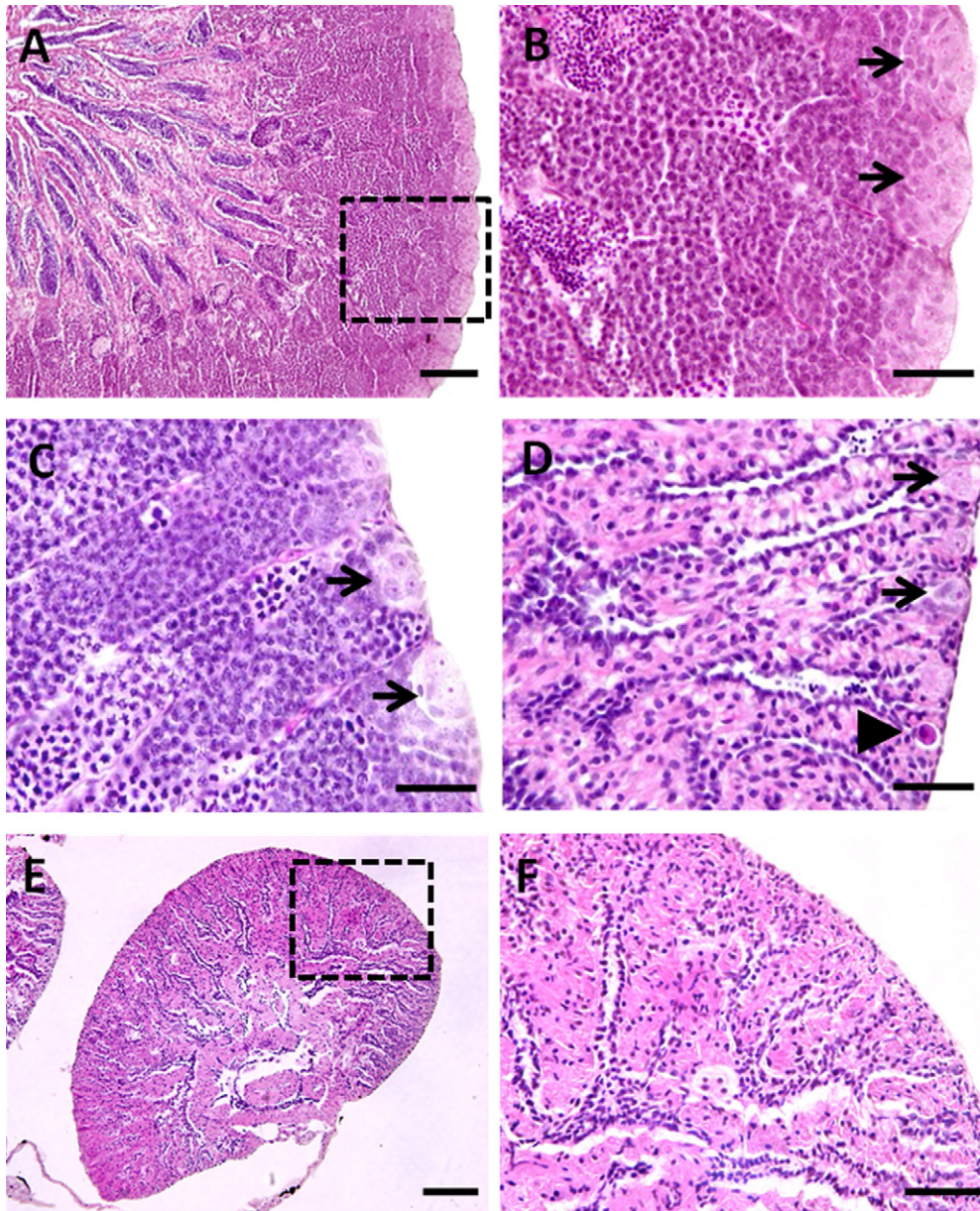


Fig. 4. Histological appearance of the testes of Patagonian pejerrey in control and Busulfan-high temperature treated groups. (A) Testis from a B0T20 male at 0 week, with thick germinal epithelium and accumulation of spermatozoa in the lumen of the efferent ducts (active spermatogenesis). (B) Detail of the box shown in (A), with large cysts of spermatogonia (arrows). (C) Testis from a B0T25 male at 8 weeks, with cysts of spermatogonia in the periphery of the gonad (arrows), spermatocytes, and spermatids. (D) Testis from a B40T25 male at 2 weeks, with a shrunken germinal epithelium with small cysts of spermatogonia (arrows) and abnormal spermatogonia (arrowhead). (E) Testis from a B40T25 (booster treatment at 4 weeks) male at 8 weeks, with virtual lack of spermatogonia. (F) Detail of the box shown in (E). Scale bars indicate 100 μm (A and E) and 30 μm (B–D and F).

treated with a booster dose of Busulfan at 4 weeks had further degrees of germinal degeneration at 8 weeks; these were much more severe at the highest temperature (25 °C; Fig. 4E and F). Determination of the number of spermatogonia per unit area of gonadal cross-section in the 2nd experiment corroborated the histological

observations, with progressive and substantial losses of germ cells in B40T25 males compared to those from B0T25 (Fig. 5). The testes of males allowed to recover at 17 °C after the Busulfan and high temperature treatments had rapid histological improvement and re-colonization of germ cells; several individuals even

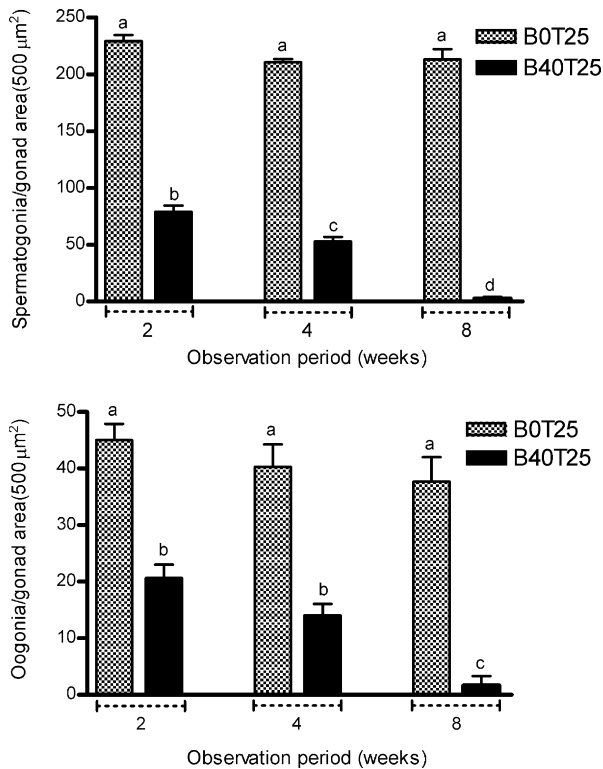


Fig. 5. Changes in the number of spermatogonia (top panel) and oogonia (bottom panel) per unit area of gonadal cross-section of Patagonian pejerrey in control (B0T25) and Busulfan-high temperature (B40T25) groups. a–d: Means without a common superscript differed ($P < 0.05$).

possessed spermatozoa in the lumen of the seminiferous lobules at 16 weeks (Table 3).

3.3. Effects of Busulfan and high temperature on the ovaries

The GSI of females reared at 25 °C and not treated with Busulfan in the second experiment had large individual variation between 2 and 8 weeks, whereas that of females treated with the drug had consistent and significant decreases (Fig. 2). Females in the B0T25 group did not have any noticeable histological changes throughout the study, with the exception of two individuals, one each on the 4th and 8th weeks. The ovaries of these fish had light atrophy of the ovigerous lamellae, fewer oocytes, and degenerating oogonia (characterized by dense eosin staining; Fig. 6A–C; Table 3). Similar histological characteristics were observed also in B40T25 females on the 2nd and 4th weeks (Fig. 6D). Moreover, two of five ovaries sampled from this group on week 4 and three of five sampled on

Table 3

Frequency of individuals per category of histological appearance of the testes and ovaries in sub-adult Patagonian pejerrey (experiment 2).

Treatment	Observation period (week)	Sex	No. fish			
			Histological category			
			I	II	III	IV
B0T25	2	♂ + ♀	5	–	–	–
			5	–	–	–
	4		5	–	–	
	8 ^a		4	1	–	–
			4	1	–	–
B40T25	2	–	5	–	–	
	4	–	5	–	–	
		–	4	1	–	
	8 ^a	–	3	2	–	
		–	–	–	5	
	12 ^b	–	–	3	2	
		–	2	3	–	
16 ^b	–	5	–	–		
	–	4	1	–		

^a Given a booster dose at 4 weeks.

^b Reared at 17 °C (recovery) between 8 weeks and sampling.

week 8 had markedly few oogonia and depositions of yellowish-brown pigments, indicating the occurrence of phagocytosis [22]. The remaining two females (from B40T25) sampled at 8 weeks were completely devoid of oogonia in all sections examined (Table 3, Fig. 6E and F). The number of oogonia per unit area of gonad cross-section steadily decreased in the experimental groups between 2 and 8 weeks (Fig. 5). Females allowed to recover at 17 °C had marked improvement of the histological appearance of the ovaries, presenting few but conspicuous cysts of oogonia in all five individuals examined at 16 weeks, and even a few cortical alveoli oocytes in one fish.

3.4. Vasa expression analysis for monitoring germ cell loss

The spatial expression of the *vasa* gene was analyzed by ISH to clarify its localization within the adult testis of Patagonian pejerrey. *Vasa* RNA transcripts were detected mainly in the cytoplasm of spermatogonia, which occupy cysts in the periphery of the gonads (Fig. 7). The signals were very faint or absent in spermatocytes, spermatids, and spermatozoa. Quantitative analysis of *vasa* expression by Real-Time RT-PCR showed that *vasa* transcript levels were different among treatments ($P < 0.05$). The lowest level of *vasa*

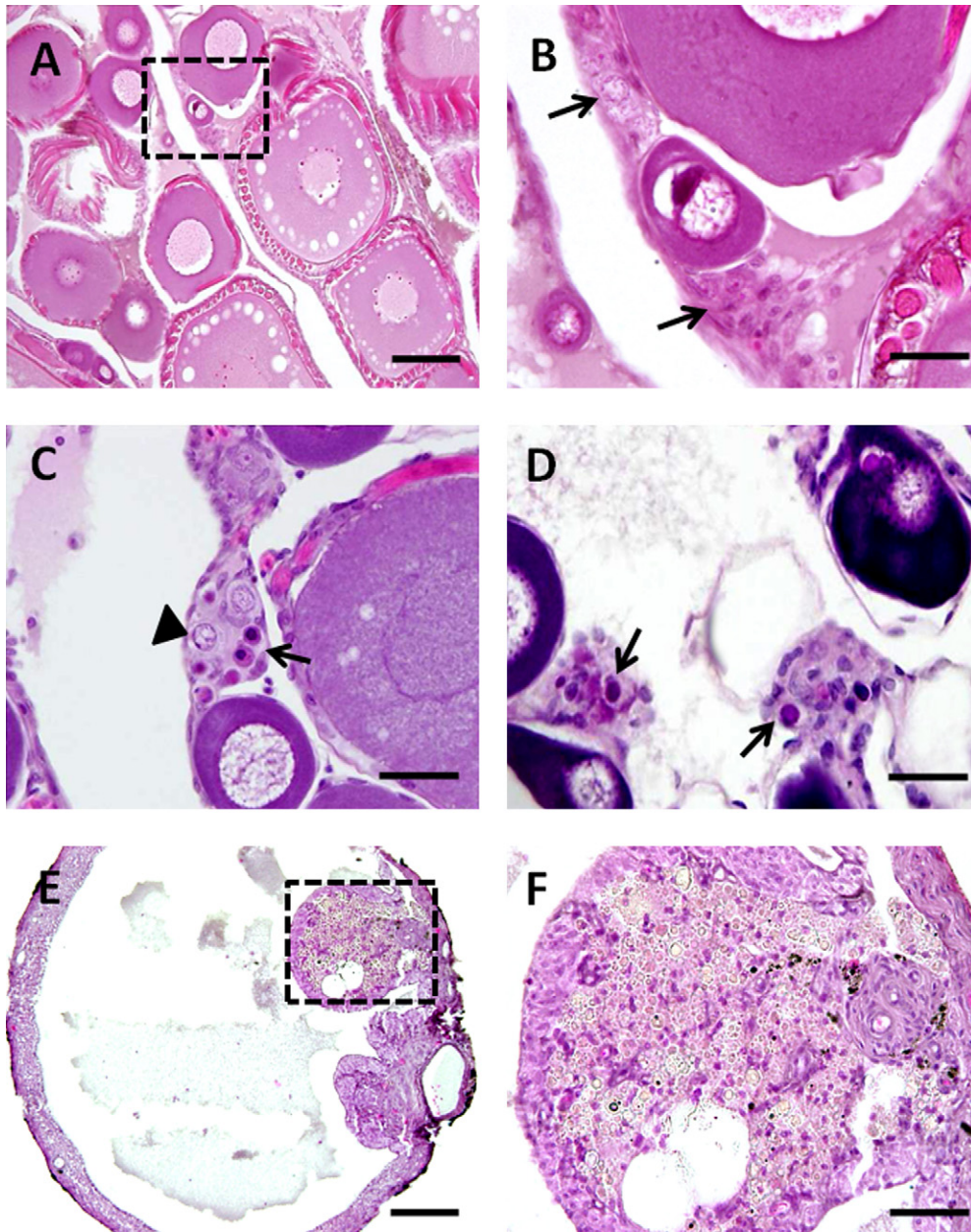


Fig. 6. Histological appearance of the ovaries of Patagonian pejerrey in control and Busulfan-high temperature treated groups. (A) Ovary of a control female at 0 week, with oocytes at various stages of development. (B) Detail of the box in (A), with prominent cysts of oogonia (arrows). (C) Ovary from a B0T25 female at 8 weeks, with normal (arrowhead) as well as abnormal (eosinophilic) oogonia (arrow). (D) Ovary from a B40T25 female at 2 weeks (note the abundance of abnormal oogonia; arrows). (E) Ovary from a B40T25 (booster treatment at 4 weeks) female at 8 weeks, with a virtual lack of oogonia. (F) Detail of the box shown in (E). Scale bars indicate 100 μm (A and E) and 30 μm (B–D and F).

transcript was recorded in B40T25 (7.7 ± 1.2), which was sixfold lower than control males (B0T20; 49.2 ± 6.5). Groups B40T20 (25.2 ± 2.1) and B20T25 (42.1 ± 4.2) had *vasa* expression levels that were intermediate between those at B40T25 and the control.

4. Discussion

Germ cell transplantation represents a powerful approach for the conservation of endangered species and the propagation of commercially important ones. Successful GCT with production of viable offspring has

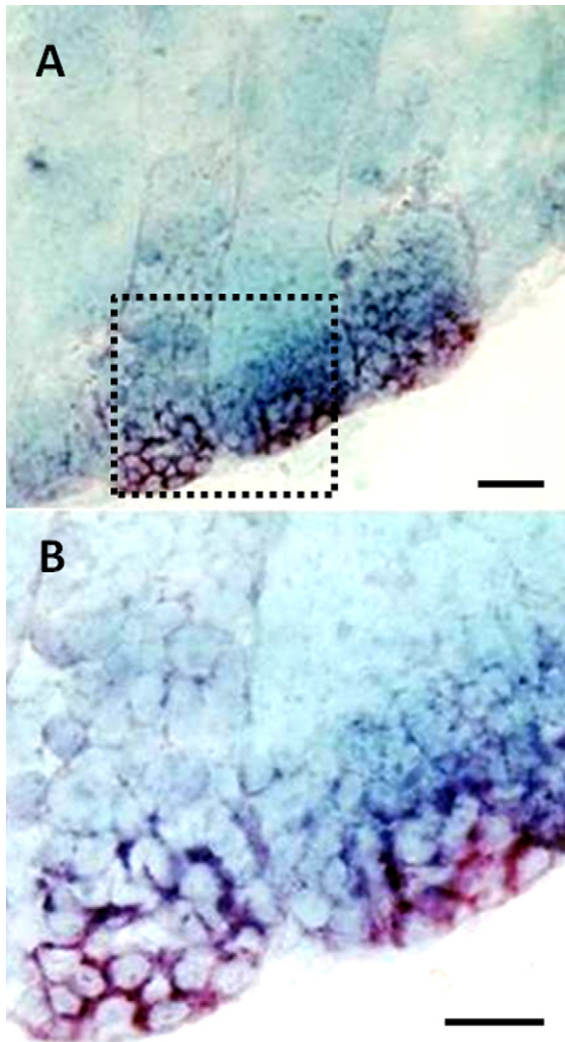


Fig. 7. Expression of *vasa* mRNA in adult Patagonian pejerrey testis. Antisense RNA transcripts were present inside the cysts of spermatogonia (B) detail of the box shown in (A)). Scale bars indicate 100 μm (A) and 20 μm (B).

been performed in fish using normal diploid [2,23,24] and triploid [16] salmonid hatchlings as hosts. In these studies, primordial germ cells (PGCs) from donors were transplanted into the body cavity of the hosts to make use of the receptivity of the gonadal primordia to the migrating PGCs during gonadal sex differentiation. Nevertheless, the approach to transplant primary oogonia or spermatogonia from adult donors directly into the gonads of adult hosts by surgical intervention, as demonstrated in mammals [25], could be an alternative to the technique using hatchlings when time to obtain gametes and offspring or the cost of producing suitable hosts is a constraint. Thus, the ability to produce suitable hosts and harvest viable gametes in a

relatively short time after GCT would enhance this approach and make it even more suitable to respond to sudden threats to endemic fish species, e.g. during environmental catastrophes.

In mammals, chemotherapy, X-ray or Gamma-ray local radiation have been utilized for germ cell depletion [25,26]. In fish, the use of radiation is difficult, as the gonads are located in the celomic cavity and, without a surgical approach, it would be almost impossible to effectively irradiate them. Another widely used strategy is the elimination of endogenous germ cells by pretreatment of recipient animals with Busulfan, a cytotoxic drug [1,3]. However, trials with Busulfan alone have not been as successful to eliminate germ cells in fish as they were in mammals (see [9]), perhaps due to differences between these taxa in their body temperature. Therefore, we tested the effectiveness of treatment with Busulfan in combination with high water temperature, an environmental factor that, in itself, causes germ cell degeneration in fish [10–15,27]. As discussed below, the results of the present study supported the assumption that a combination of both treatments is more efficient than either treatment alone.

In this study, high temperature (25 °C) alone caused mild regression of the testes and ovaries of *O. hatcheri* after 8 weeks. The observed changes included the disappearance of all intermediate stages of spermatogenesis between spermatogonia and mature sperm in males and shrinkage of the ovary, thickening of the ovarian tunica, and incipient hypertrophy of the ovigerous lamella in females. Ito et al. also recorded a similar degree of gonadal degeneration in the congeneric (but comparatively warm water) species *O. bonariensis* after exposure to 29 °C for 4 weeks and noted that this level of regression was equivalent to that observed in wild animals during summer [13,14]. They concluded that such degeneration represented a natural response to elevated temperature during the annual thermal (and reproductive) cycle. Nevertheless, further exposure to the same temperature resulted in progressive gonadal degeneration and ultimately sterility [13,14]. In this context, the histological degeneration seen in *O. hatcheri* after 8 weeks at 25 °C probably represents also an initial response to “summer” and yet, continued exposure to this condition might lead to further degeneration. This possibility must be explored in future studies, because of the obvious advantages of non-chemical methods, as well as potential limitations of the chemical treatment with Busulfan (see below).

In contrast to treatment with temperature alone, Busulfan caused marked gonadal degeneration, apparent after only 2 weeks. In addition to the changes noted

in the high temperature (25 °C) groups, Busulfan-treated animals had further loss of germ cells in both sexes and intense phagocytic activity by the follicle cells, leading to atrophy of the ovigerous lamellae in females. Histological degeneration of the ovaries, but not that of the testes, involved widespread occurrence of macrophage aggregates, a characteristic previously reported in ovaries of pejerrey *O. bonariensis* females during prolonged heat stress [14] and other species of fish after exposure to chemical contaminants [22,28]. Further degeneration in Busulfan-treated groups was clearly dose-dependent, comprising both the nominal dosage and the frequency of treatment, and temperature-dependent. Thus, as expected, the highest dose and the repeated (booster) treatment, particularly in combination with high temperature (25 °C), resulted in more severe loss of germ cells to the point that some individuals examined at 8 weeks had no noticeable germ cells in any of the histological sections. High temperature and repeated treatments were also more effective to deplete germ cells in Nile tilapia, but in this case, the authors attributed the effectiveness of high temperatures to the acceleration of the cell cycle [3].

Judging by the proportion of fish with few or no germ cells during histological observation and cell counting, and the results of *vasa* expression, males of Patagonian pejerrey were more easily depleted of germ cells than females. However, the results of recovery post-treatment at low temperature indicated that no individual became completely sterile, regardless of sex or treatment conditions. This observation suggests that, for efficient depletion of germ cells in *O. hatcheri*, the Busulfan treatment period should be extended or combined with higher temperatures. Another alternative could be to increase the dosage or the frequency of treatment with Busulfan. However, it has been reported that high doses of Busulfan can induce severe bone marrow depression and cause death in mammals [4,25]. In the case of *O. hatcheri*, we observed that some individuals developed ulcerations shortly after Busulfan treatment and mortalities were observed chiefly in fish receiving the highest dose of the drug. Thus, the highest dose (40 mg/kg body weight, booster administration on the 4th week) tested probably approximates the tolerance limit of this species. It is noteworthy that Busulfan-induced mortality was more frequent in females than males at the high temperature (25 °C), whereas in a previous study with heat stress alone, we observed selective mortality of *O. bonariensis* males rather than females [14]. Ongoing investigations are studying protocols to overcome the toxicity of Busulfan and heat and to maximize sterility and survival.

The histological observation after a period of recovery at low temperature (17 °C) revealed that within 8 weeks after the treatment, the gonads were repopulated with germ cells and, in most cases, contained functional gametes. This is an indication that the gonial cells that were not destroyed by the treatment retained the capacity to undergo gametogenesis. This observation also suggests that somatic cells (such as Sertoli and Leydig cells in males and follicular cell in females), which support the proliferation and development of the germ cells, were not critically affected by Busulfan and heat treatments. Hence, we surmise that they would be able to support also transplanted germ cells if these cells are compatible with the host's gonadal environment. Moreover, Busulfan treatment also did not eradicate all endogenous spermatogonia in mammals, leaving some stem cells that would re-initiate spermatogenesis in the host, together with transplanted spermatogonia [1,29]. This would represent a practical problem for collection of donor-derived gametes, as they will have to be separated from those of the host. Still, previous work on mice has shown that the fertility of recipient animals after germ cell transplantation was lower in animals sterilized almost completely by treatment with Busulfan as adults, than in recipients prepared by fetal exposure to the drug and where ablation of endogenous germ cell was incomplete [30]. Thus, further trials with *O. hatcheri* are needed to compare the fertility of individuals with varying degrees of sterility.

In conclusion, the results of this study indicate that a combination treatment with Busulfan and high temperature might be effective to deplete endogenous spermatogonia and oogonia of *O. hatcheri* hosts, and possibly in other species, in preparation for GCT. Further improvements could lead to drastic reduction of the endogenous germ cell population, if not complete sterilization of hosts, within a few weeks. Such development will increase the probability that such a technique might be useful in situations that require immediate action, e.g. during environmental disasters and impending loss of unique genetic materials. Also, this study demonstrated that the level of (germ cell-specific) *vasa* expression in the gonads provides real-time insight regarding the size of the remaining germ cell population and this knowledge may prove instrumental for further optimization of protocols for efficient host preparation.

Acknowledgements

During this study, the senior author was supported by a scholarship from the Ministry of Education, Culture,

Sports, Science and Technology (MEXT) of Japan, which is gratefully acknowledged. We are indebted to the staff of Field Science Center, Yoshida Station, Tokyo University of Marine Science and Technology, for kindly supplying the fish.

References

- [1] Brinster RL, Zimmermann JW. Spermatogenesis following male germ cell transplantation. *Proc Natl Acad Sci USA* 1994;91:11298–302.
- [2] Takeuchi Y, Yoshizaki G, Takeuchi T. Generation of live fry from intraperitoneally transplanted primordial germ cells in rainbow trout. *Biol Reprod* 2003;69:1142–9.
- [3] Lacerda SMSN, Batlouni SR, Silva SBG, Homem CSP, Franca LR. Germ cells transplantation in fish: the Nile-tilapia model. *Anim Reprod* 2006;2:146–59.
- [4] Brinster CJ, Ryu BY, Avarbock MR, Karagenc L, Brinster RL, Orwig KE. Restoration of fertility by germ cell transplantation requires effective recipient preparation. *Biol Reprod* 2003;69:412–20.
- [5] Brinster RL, Avarbock MR. Germline transmission of donor haplotype following spermatogonial transplantation. *Proc Natl Acad Sci USA* 1994;91:11303–7.
- [6] Van den Aardweg GJ, de Ruiter-Bootsma AL, Kramer MF, Davids JA. Growth and differentiation of spermatogenic colonies in the mouse testis after irradiation with fission neutrons. *Radiat Res* 1983;94:447–63.
- [7] Yong GP, Goldstein M, Phillips DM, Sundaram K, Gunsalus GL, Bardin CW. Sertoli cell-only syndrome produced by cold ischemia. *Endocrinology* 1988;122:1047–82.
- [8] Rockett JC, Mapp FL, Garges JB, Luft JC, Mori C, Dix DJ. Effects of hyperthermia on spermatogenesis, apoptosis, gene expression, and fertility in adult male mice. *Biol Reprod* 2001;65:229–39.
- [9] Billard R. Attempts to inhibit testicular growth in Rainbow trout with antiandrogens (Cyproterone, Cyproterone acetate, Oxy-methalone) and Busulfan given during the period of spermatogenesis. *Gen Comp Endocrinol* 1982;48:33–8.
- [10] Strüssmann CA, Saito T, Takashima F. Heat induced germ cell deficiency in the teleosts *Odontesthes bonariensis* and *Patagonina hatcheri*. *Comp Biochem Physiol* 1998;119A:637–44.
- [11] Ito LS, Yamashita M, Strüssmann CA. Histological process and dynamics of germ cell degeneration in pejerrey *Odontesthes bonariensis* larvae and juveniles during exposure to warm water. *J Exp Zool* 2003;297A:169–79.
- [12] Ito LS, Yamashita M, Takahashi C, Strüssmann CA. Gonadal degeneration in sub-adult male pejerrey (*Odontesthes bonariensis*) during exposure to warm water. *Fish Physiol Biochem* 2003;28:421–2.
- [13] Ito LS, Cornejo AM, Yamashita M, Strüssmann CA. Thermal threshold and histological process of heat-induced sterility in adult pejerrey (*Odontesthes bonariensis*): a comparative analysis of laboratory and wild specimens. *Physiol Biochem Zool* 2008;81:775–84.
- [14] Ito LS, Takahashi C, Yamashita M, Strüssmann CA. Warm water induces apoptosis, gonadal degeneration, and germ cell loss in sub-adult pejerrey *Odontesthes bonariensis* (Pisces, Atheriniformes). *Physiol Biochem Zool* 2008;81:762–74.
- [15] Byerly MT, Fat-Halla SI, Betsill RK, Patiño R. Evaluation of short-term exposure to high temperature as a tool to suppress the reproductive development of channel catfish for aquaculture. *North Am J Aquac* 2005;67:331–9.
- [16] Okutsu T, Shikina S, Kanno M, Takeuchi Y, Yoshizaki G. Production of trout offspring from triploid salmon parents. *Science* 2007;317:1517.
- [17] Arai K. Genetic improvement of aquaculture finfish species by chromosome manipulation techniques in Japan. *Aquaculture* 2001;197:205–28.
- [18] Kapuscinski AR, Patroski TJ. Genetic methods for biological control of non-native fish in the Gila River Basin. Contract report to the U.S. Fish and Wildlife Service. University of Minnesota, Institute for Social, Economic and Ecological Sustainability, St. Paul, Minnesota. Minnesota Sea Grant Publication (F20); 2005.
- [19] Maclean N, Rahman MA, Sohm F, Hwang G, Iyengar A, Ayad H, et al. Transgenic tilapia and the tilapia genome. *Gene* 2002;295:265–77.
- [20] Strüssmann CA, Calsina Cota JC, Phonlor G, Higuchi H, Takashima F. Temperature effects on sex differentiation of two South American atherinids, *Odontesthes argentinensis* and *Patagonina hatcheri*. *Environ Biol Fish* 1996;47:143–54.
- [21] Ogawa T, Arechaga JM, Avarbock MR, Brinster RL. Transplantation of testis germinal cells in to mouse seminiferous tubules. *Int J Dev Biol* 1997;41:111–22.
- [22] Scott GG, McArthur NH, Tarpley R, Jacobs V, Sis RF. Histopathological survey of ovaries of fish from petroleum production and control sites in the Gulf of Mexico. *J Fish Biol* 1981;18:261–9.
- [23] Yoshizaki G, Tago Y, Takeuchi Y, Sawatari E, Kobayashi T, Takeuchi T. Green fluorescent protein labeling of primordial germ cells using a non-transgenic method and its application for germ cell transplantation in salmonidae. *Biol Reprod* 2005;73:88–93.
- [24] Kobayashi T, Takeuchi Y, Takeuchi T, Yoshizaki G. Generation of viable fish from cryopreserved primordial germ cell. *Mol Reprod Dev* 2007;74:207–13.
- [25] Ogawa T, Dobrinski I, Brinster RL. Recipient preparation is critical for spermatogonial transplantation in the rat. *Tissue Cell* 1999;31:461–72.
- [26] Brinster RL. Germ cell transplantation. *Science* 2002;296:2174–6.
- [27] Strüssmann CA, Patiño R. In: Knobil E, Neill JD, editors. Sex determination, environmental. San Diego: Academic Press; 1999. p. 402–9 [Encyclopedia of Reproduction, V4].
- [28] Blazer VS. Histopathological assessment of gonadal tissue in wild fishes. *Fish Physiol Biochem* 2002;26:85–101.
- [29] Russell LD, Griswold MD. Spermatogonial transplantation—an update for the millennium. *Mol Cell Endocrinol* 2000;161:117–20.
- [30] Shinohara T, Inoue K, Ogonuki N, Kanatsu-Shinohara M, Miki H, Nakata K, et al. Birth of offspring following transplantation of cryopreserved immature testicular pieces and in vitro microinsemination. *Hum Reprod* 2002;17:3039–45.